



Guide to Paediatric Hip Ultrasound




Table of Contents

Introduction	1
About VicHip	2
Ultrasound Positioning	3
Ultrasound Quality	3
Ultrasound Checklist	4
Mid Section of Acetabular Roof	5
Labrum	6
Lower Limb of Os Ilium	7
Mid Section of Femoral Head	8
Measurements	9
Standard Lines:	10
Base Line	10
Bony Roof	11
Cartilage Roof Line	12
Turning Point	13
Alpha Angle	14
Beta Angle	15
Percentage Femoral Head Coverage	16
Morphology: Bony Roof	18
Morphology: Bony Rim	19
Morphology: Cartilagenous Roof	20
Hip Classification	21
Contact	22
References	22

Introduction


Welcome to our clinician guide designed to help diagnose and assess hip dysplasia using ultrasound imaging. Our goal is to support clinicians, radiographers and radiologists who perform and report on paediatric hip scans.

Hip ultrasound remains the most important tool in the detection and monitoring of hip dysplasia in infants. It is crucial to have high-quality scans and interpretations to guide care and treatment decisions, highlighting the importance of expertise in this field.

Our guide aims to enhance ultrasound quality standards for optimal patient outcomes. It does not replace proper training, experience or accreditation. Instead, it seeks to enrich existing knowledge and expertise, and strengthen hip care and services in Victoria.

For more information and resources, please scan the QR code or visit:

www.vichip.org.au/health-professionals/



About VicHip

The Victorian hip dysplasia registry, or VicHip, is a clinical registry of patients diagnosed with hip dysplasia in Victoria. We are a passionate group of families, researchers and hip health experts dedicated to improving the care and treatment of hip dysplasia to achieve the best possible patient outcomes.

VicHip is made possible thanks to the Victorian hip dysplasia community, funding from the Australian Government and the ongoing commitment from our [partners and supporters](#). We are so grateful for their support.



VicHip is funded by the Australian Government Department of Health and Aged Care under the Medical Research Future Fund grant 2015989.

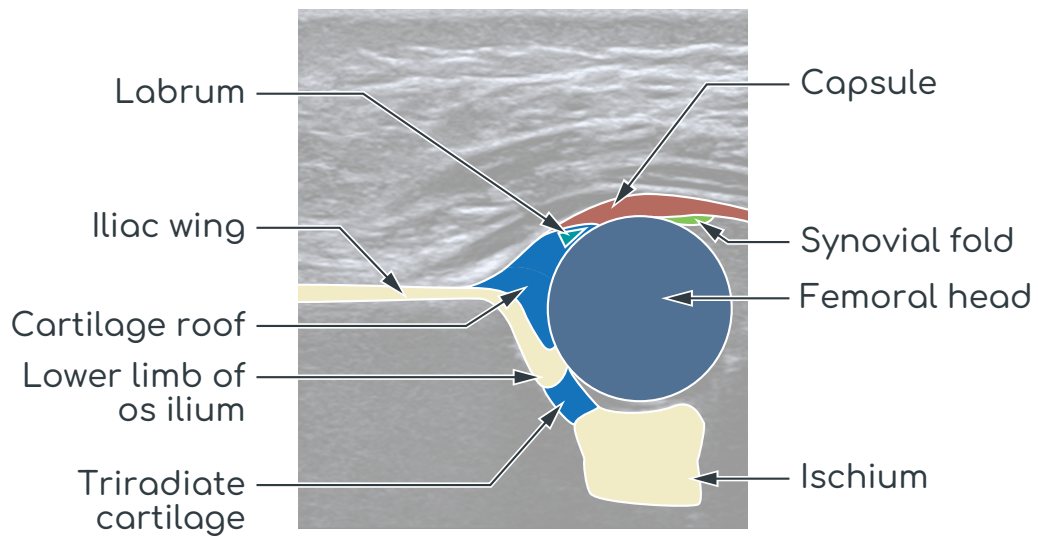
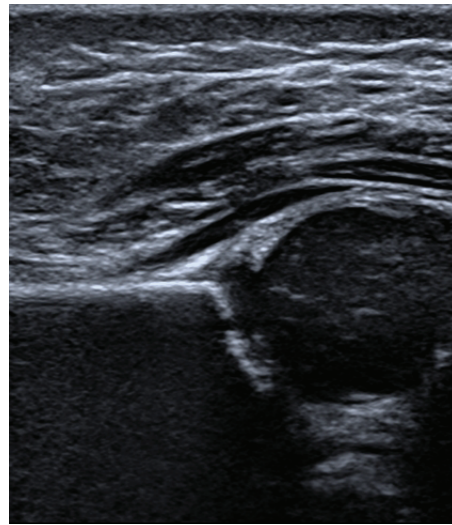
Ultrasound Positioning

- Supine
- Hip flexed to 90°
- Probe parallel to ground for geometric measures and coverage:
 - Note chondro-osseous junction usually not seen with this positioning
- Probe at right angle to ground for axial views and stability measurements

Ultrasound Quality

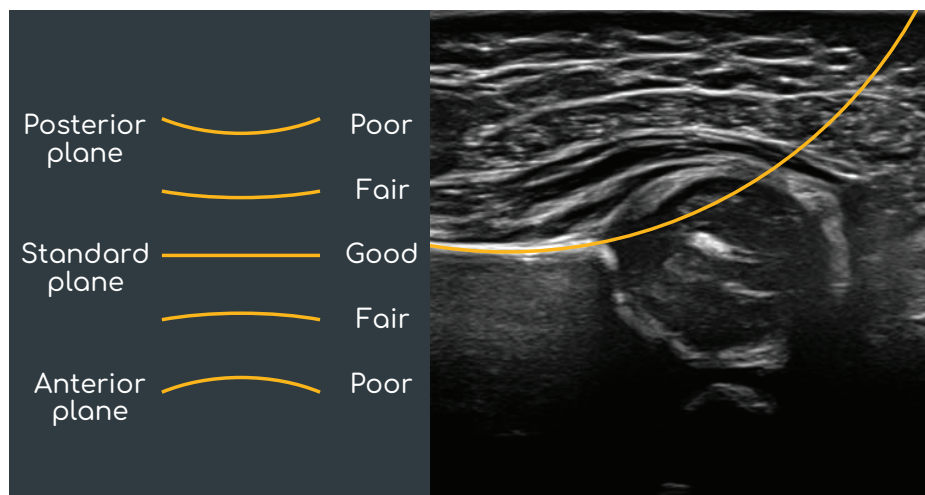
- Mid section acetabular roof
- Labrum
- Inferior limb of os ilium

Ultrasound Checklist



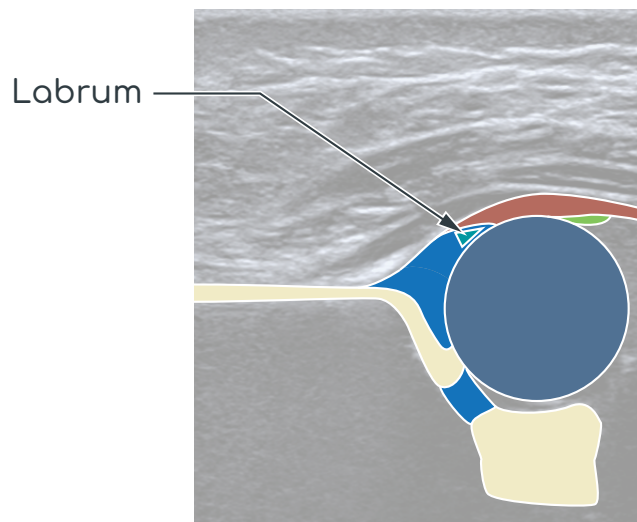
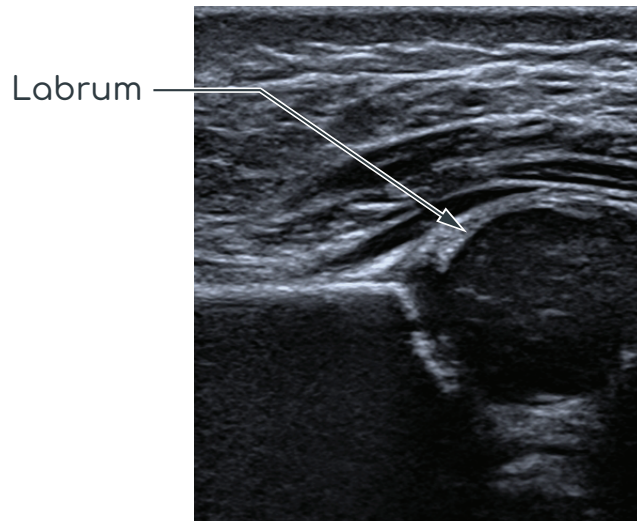
Mid Section of Acetabular Roof

- The mid section is reached when, having identified the posterior plane, the plane rotates around the lower limb of the os ilium until it leaves the gluteal fossa. This easily identified concavity straightens
- The iliac silhouette above the bony rim is straight and parallel to the transducer (and the edge of the monitor)
- Posterior section — goes away from the transducer (iliac contour is concave and goes to the right on the monitor)
- Mid section — the iliac silhouette parallel to the transducer (parallel to the monitor)
- Anterior section — the iliac silhouette angles towards the transducer (iliac echo leans to the left on the monitor)
- The contour and the silhouette of the iliac bone are straight and parallel to the probe



Labrum

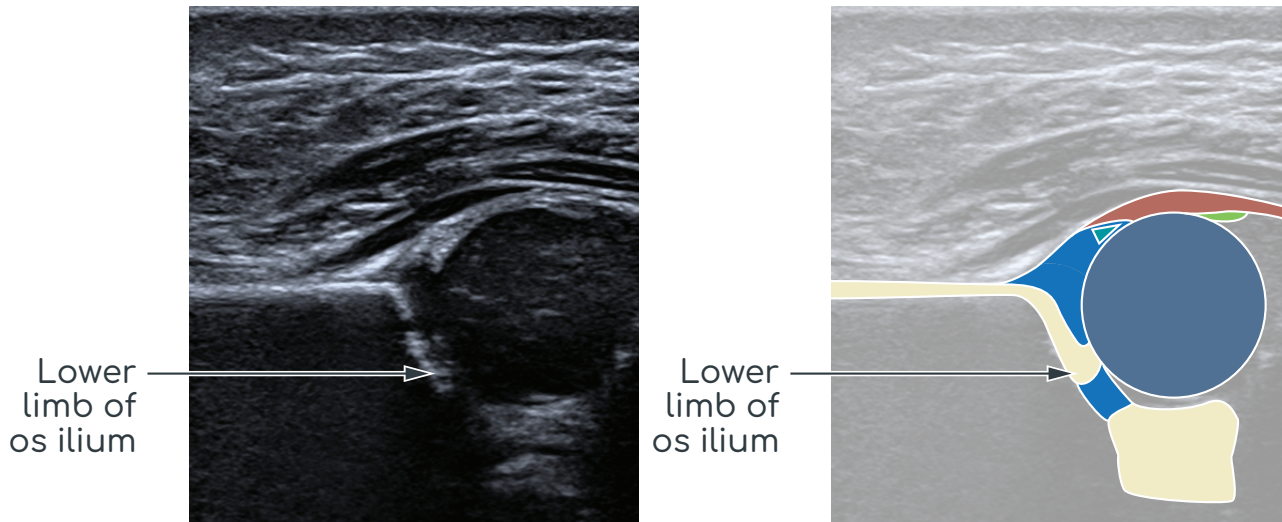
- The acetabular labrum is triangular in cross-section and is on the inner side of the joint capsule. There is no adhesion between the joint capsule and the labrum and there is a small recess between them. The base of the labrum is fixed to the hyaline cartilage acetabular roof



- This is represented by the triangular echogenic structure extending laterally from the cartilaginous acetabular rim and was recorded as:
 - a) well-defined;
 - b) blurred; or
 - c) could not be identified

Lower Limb of Os Ilium

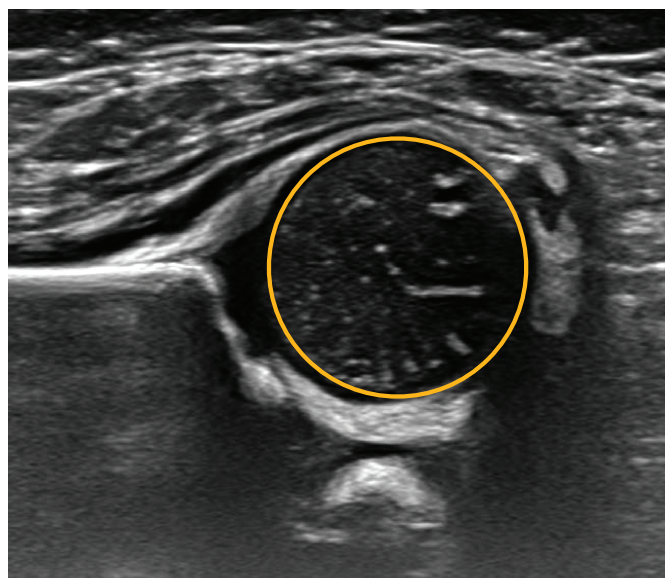
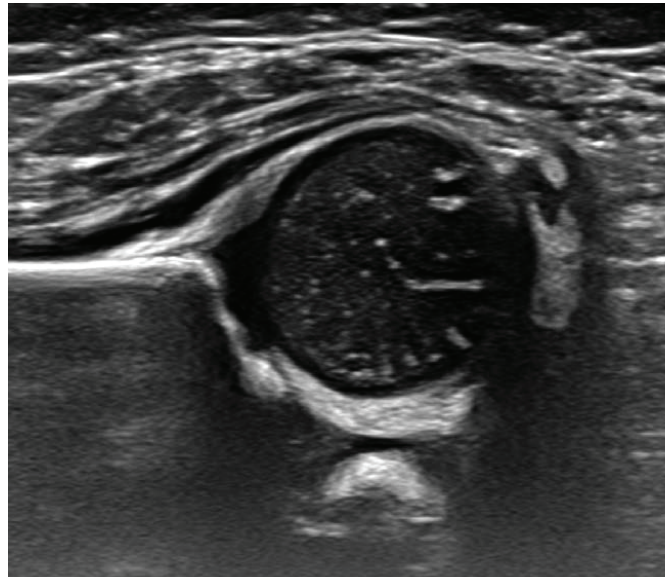
- The lower limb of the os ilium measures 1–3mm in size depending on the age of the baby



- The lower limb must be clearly identified. It is an essential marker of the correct sectional plane and must be clearly seen on the sonogram unless the hip is decentered
- Anatomically the lower limb of the os ilium is approximately half way between the anterior and posterior rims of the acetabulum and casts an acoustic shadow
- Caudal to the lower limb is the hypoechoic triradiate cartilage
- Caudal to this the bright echo of the ischial bone will be seen in some planes
- The lower limb of the os ilium is ultrasonically the center of the acetabulum
- The lower limb of the os ilium must be a clearly defined echo and must not be a faint or fading echo

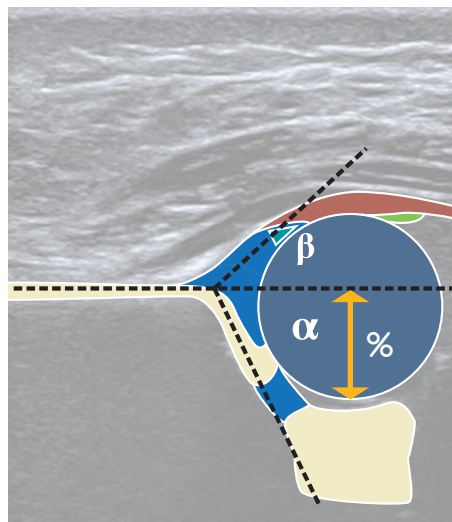
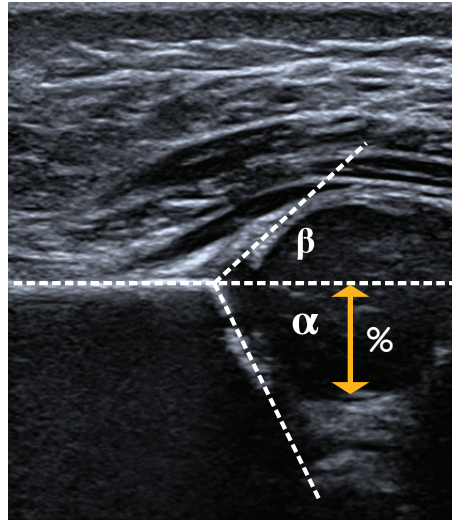
Mid Section of Femoral Head

- The mid section of the femoral head refers to obtaining a truly circular cross section of the structure
- Oval femoral head indicates cranio-caudal tilt of ultrasound beam



Measurements

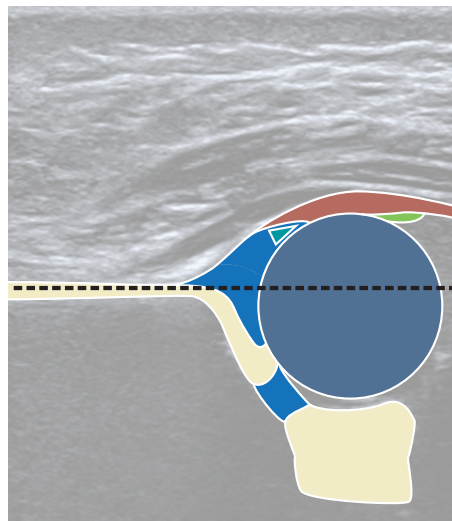
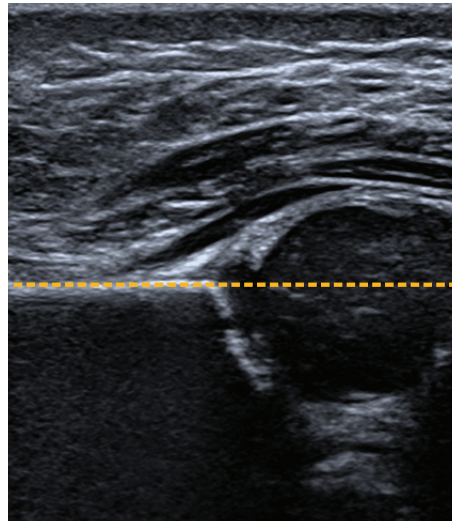
- Standard lines:
 - Alpha angle
 - Beta angle
 - Percentage femoral head coverage



Standard Lines

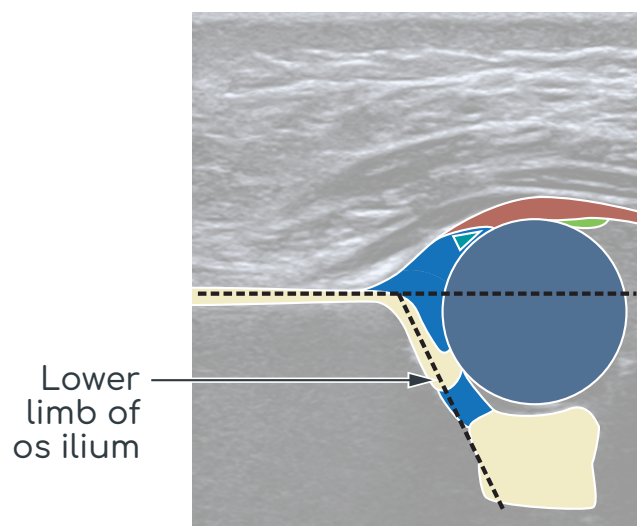
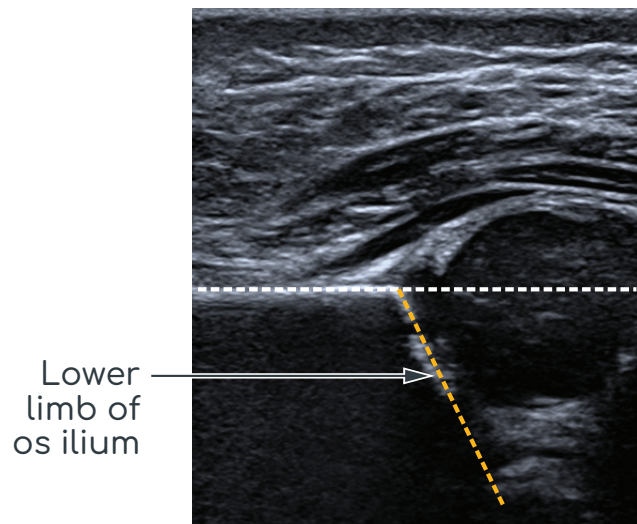
Base Line

- The base line should be drawn from the point at which the proximal perichondrium becomes the periosteum of the ilium, caudally and parallel to the ilium itself



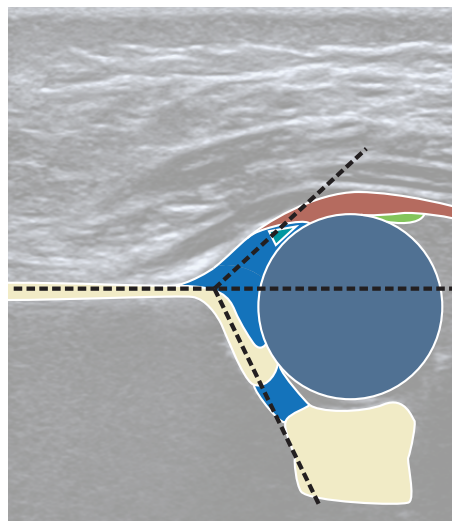
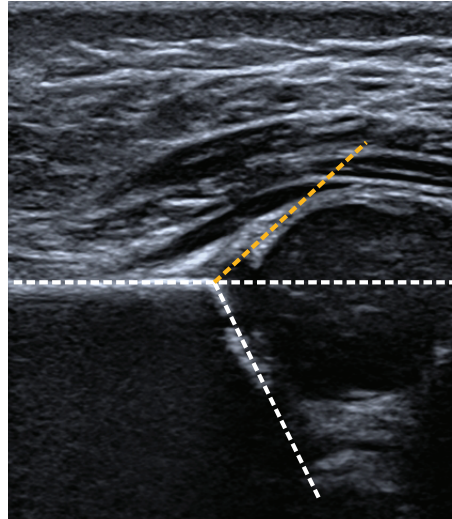
Bony Roof

- The bony roof line is drawn from the inferior rim of the os ilium, tangentially to the bony roof

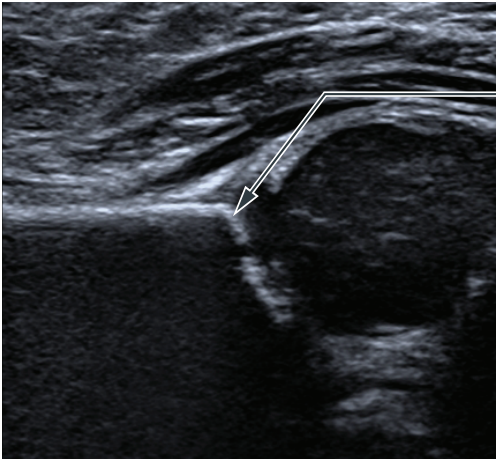


Cartilage Roof Line

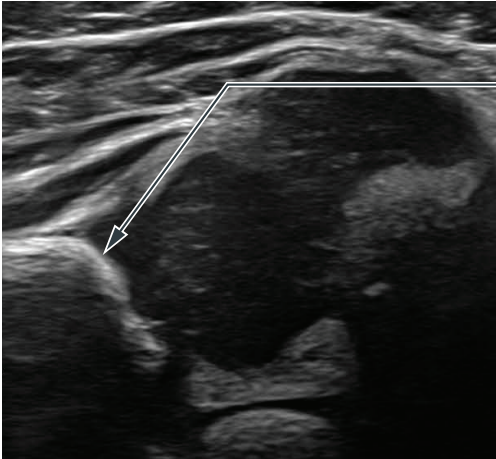
- The cartilage roof line connects the osseus rim (turning point from convexity to concavity) with the middle of the labrum



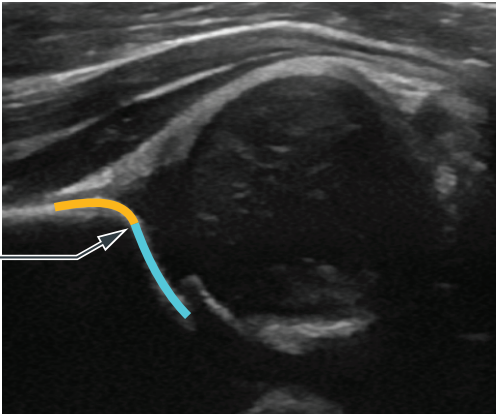
Turning Point



Turning point



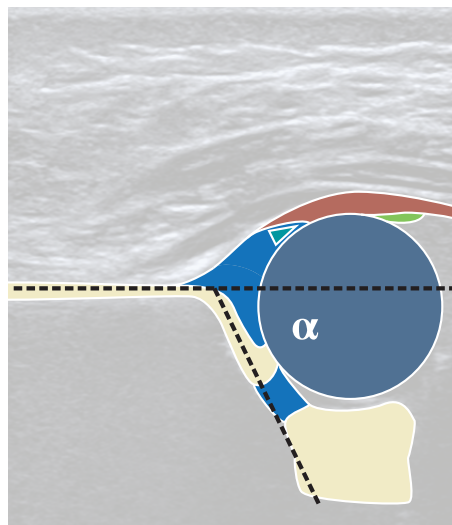
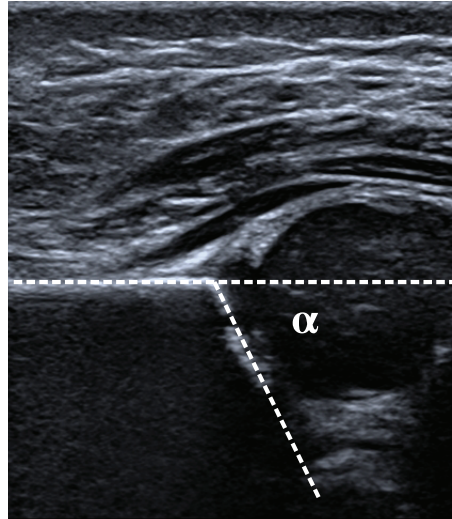
Turning point



Turning point
concavity to
convexity

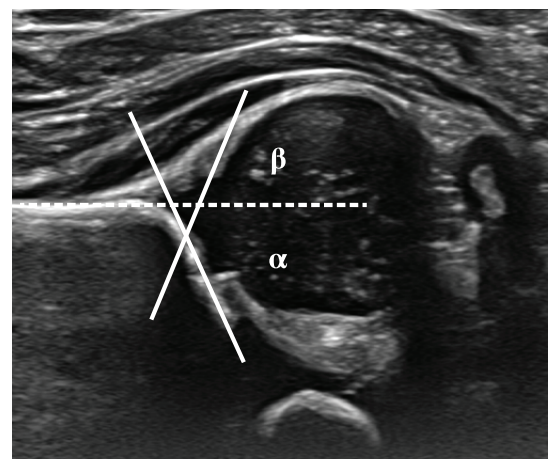
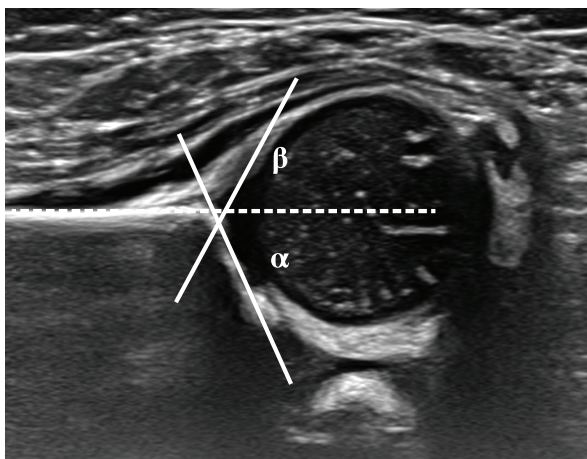
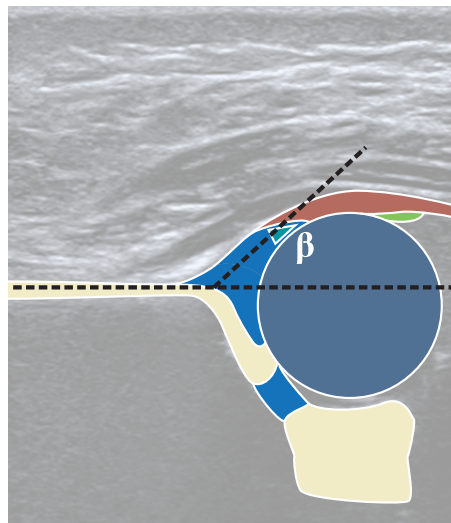
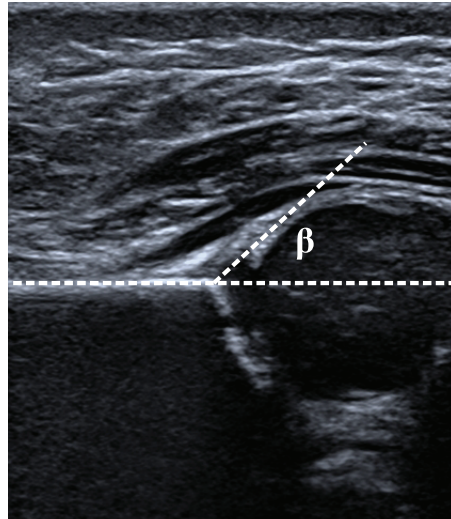
Alpha Angle

- The alpha angle is measured between the base line and the bony roof line and quantifies the bony acetabular roof



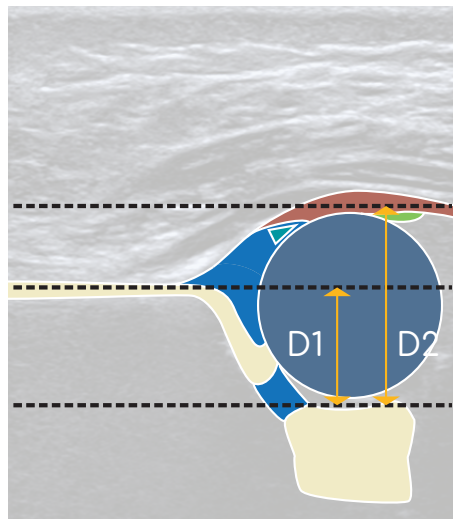
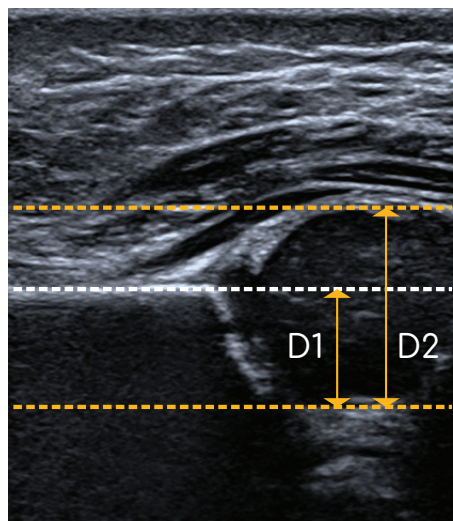
Beta Angle

- The beta angle is the angle between the base line and the cartilage roof line, and quantifies the cartilaginous acetabular roof

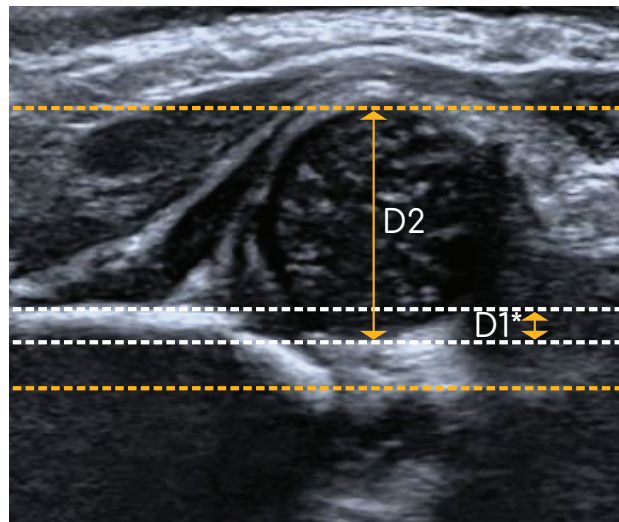


Percentage Femoral Head Coverage

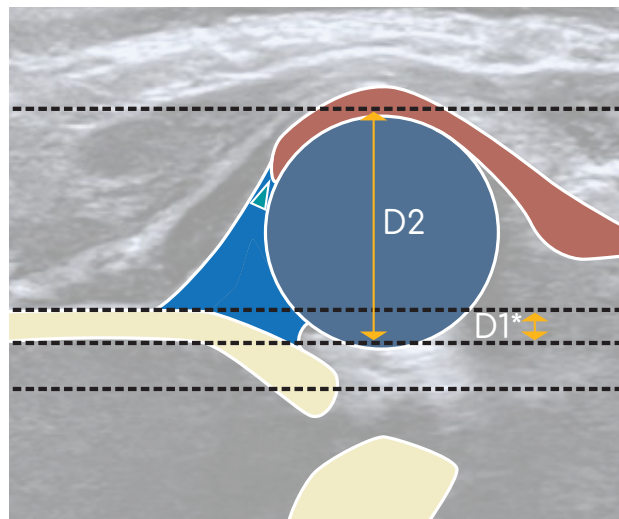
- The percentage femoral head coverage is measured in the mid axial plane of the hip as a percentage of the head under coverage of the bony acetabulum



- If the hip is subluxated or dislocated four lines are required to determine the percentage femoral head coverage




$D1^*/D2 \%$

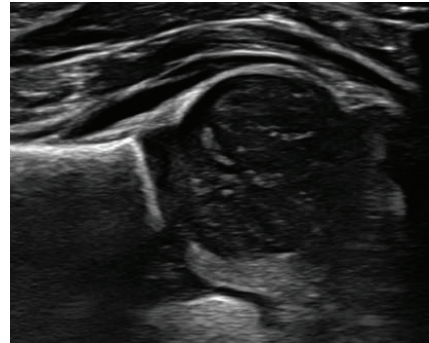


$D1^*/D2 \%$


Morphology: Bony Roof



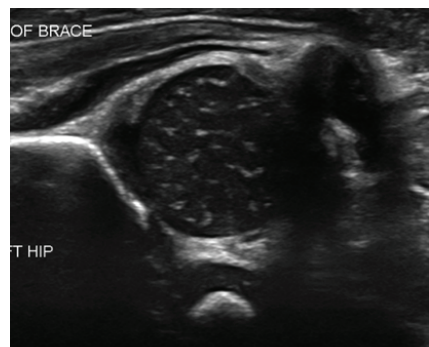
Bony roof good




Bony roof good



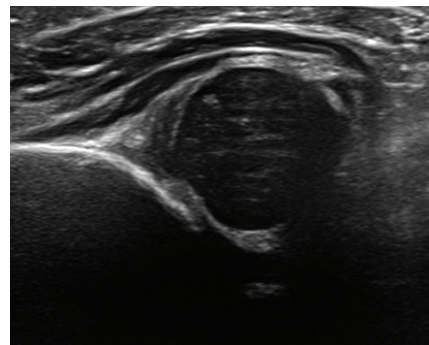
Bony roof deficient



Bony roof deficient




Bony roof poor

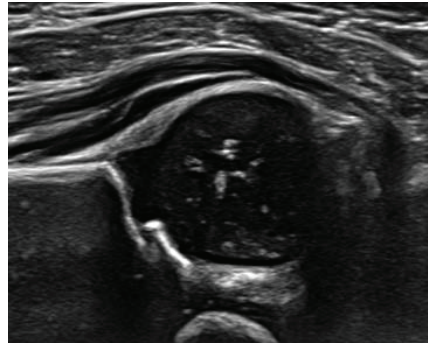


Bony roof poor

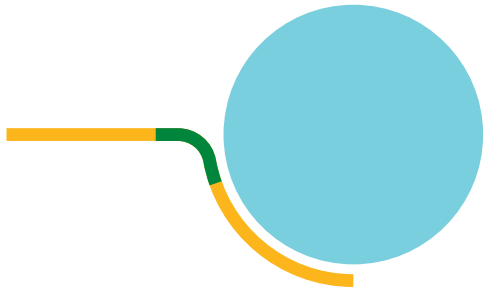
Morphology: Bony Rim



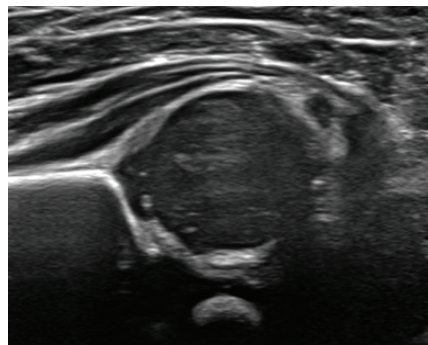
Bony rim sharp




Bony rim sharp



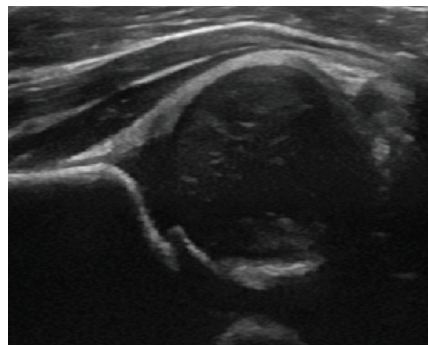
Bony rim blunt




Bony rim blunt



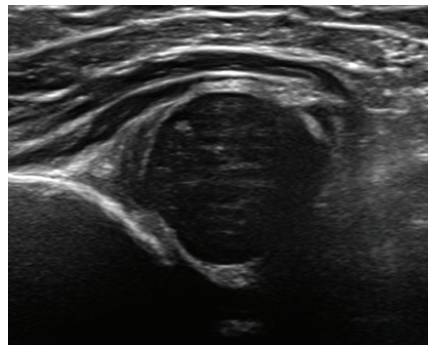
Bony rim rounded



Bony rim rounded




Bony rim flat

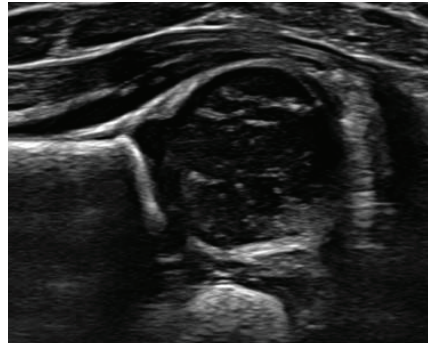


Bony rim flat


Morphology: Cartilagenous Roof



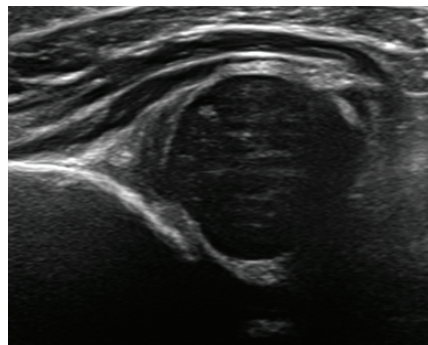
Narrow




Narrow



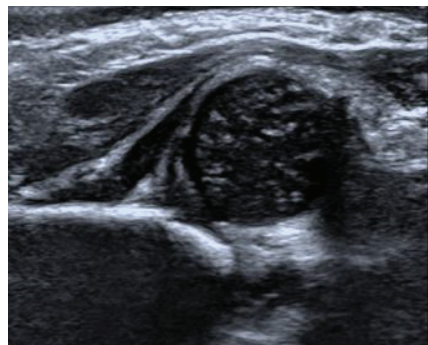
Broad undisplaced




Broad undisplaced



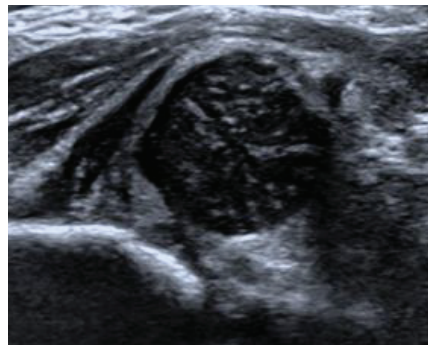
Broad displaced



Broad displaced



Interposed



Interposed

Hip Classification

Type	Maturity	Bony roof	Alpha angle	Bony rim	Cartilage roof	Beta angle	Age
I	Mature	Good	$\geq 60^\circ$	Sharp	Good		All
IIa	Immature	Adequate	$50-59^\circ$	Blunt	Good		<3 months
IIb	Delayed	Deficient	$50-59^\circ$	Rounded	Adequate		>3 months
IIc	Stable or unstable	Severely deficient	$43-49^\circ$	Round/Flat	Adequate	$<77^\circ$	All
D	Decentering	Severely deficient	$43-49^\circ$	Round/Flat	Displaced	$>77^\circ$	All
III	Eccentric	Poor	$<43^\circ$	Flat	Labrum displaced upward		All
IV	Eccentric	Poor	$<43^\circ$	Flat	Labrum displaced downward		All

Contact

Victorian hip dysplasia registry (VicHip)
Murdoch Children's Research Institute
50 Flemington Road, Parkville
Victoria 3052 Australia
vichip@mcri.edu.au

References

Graf, R., Mohajer, M. & Plattner, F. Hip sonography update. Quality-management, catastrophes — tips and tricks. *Med Ultrason* 15, 299–303 (2013).

Harcke, H. T. & Pruszczyński, B. Hip ultrasound for developmental dysplasia: the 50% rule. *Pediatr Radiol* 47, 817–821 (2017)